

Atypical mycobacterial tenosynovitis and bursitis of the wrist

Hatice Tuba Sanal, Fatih Zor, Murat Kocaoğlu, Nail Bulakbaşı

ABSTRACT

Atypical mycobacterial tenosynovitis of the wrist can easily be misdiagnosed as synovial chondromatosis. Both sonography and magnetic resonance imaging plays an important role in depicting “rice bodies” within the distended tendon sheaths and bursae of atypical mycobacterial infection. An endemic place for *Mycobacterium* species and the occupation of the patient should raise the suspicion for the disease. Polymerase chain reaction of the distended tendon fluid is a sensitive, specific and rapid method in identification of the mycobacteria.

Key words: • atypical mycobacterium infections • tenosynovitis • wrist • magnetic resonance imaging • polymerase chain reaction

Atypical mycobacteria are omnipresent in the environment and rarely may cause tenosynovitis of the distal upper extremities (1, 2). Because of low clinical suspicion, their diagnosis is usually delayed, with consequent increased morbidity. Increased awareness of the disease, familiarity with the imaging features, and identification of different *Mycobacterium* species by using polymerase chain reaction (PCR) lead rapid detection of the causative agent and proper treatment of the disease.

We report a case of atypical mycobacterial tenosynovitis and bursitis of the wrist, with emphasis on the imaging, which was about to be misdiagnosed as synovial chondromatosis.

Case report

A 22-year-old farmer presented with a painless, volar soft tissue mass over his left wrist, which had been slowly growing for 2–3 years. He had no history of penetrating injury nor any medical history of systemic arthritis or tuberculosis. He was afebrile. Physical examination revealed a 13-cm, soft, immobile, non-pulsatile mass over the volar aspect of the left wrist, extending into the palm and 4 cm above the wrist. No other joints were affected. Erythrocyte sedimentation rate, C-reactive protein, rheumatoid factor, and antinuclear antibodies were all within normal limits.

Conventional radiographs of the hand were unremarkable, except for increased soft tissue opacity over the left wrist with no calcification or osseous abnormality. Hemangioma was first suspected on inspection of the bluish swelling over the skin. An ultrasound examination was done, showing multiple, well-defined, slightly echogenic bodies in a large effusion (Fig. a). Magnetic resonance imaging (MRI) examination was then performed; MR images demonstrated massive distension of the flexor retinaculum, flexor tendon sheaths, and radial and ulnar bursae affecting the palm and distal forearm. Following intravenous administration of gadolinium, there was enhancement in the moderately and smoothly thickened bursal wall and synovial membrane surrounding the flexor tendons, indicating bursitis and synovitis, respectively (Fig. b, c). There were innumerable small millimetric nodules within the distended sheaths and bursae, hypointense on T2-weighted images, slightly hyperintense on T1-weighted images, and hypointense on gradient echo sequences (Fig. d, e). The patient's living place was known to be endemic for tuberculosis species; this fact and his occupation led us to request microbiologic examination of the aspirated material from the lesion. PCR identifying *Mycobacterium marinum* was found in the aspirated fluid. A radical flexor tenosynovectomy with extraction of rice bodies was performed. The patient was also treated with a course of oral tetracycline.

From the Departments of Radiology (H.T.S. ✉ tubasanal@yahoo.com, M.K., N.B.), and Plastic and Reconstructive Surgery (F.Z.), Gülhane Military Medical Academy, Ankara, Turkey.

Received 6 November 2007; revision requested 3 January 2008; revision received 8 January 2008; accepted 24 January 2008.

Published online 27 October 2009
DOI 10.4261/1305-3825.DIR.1506-07.1

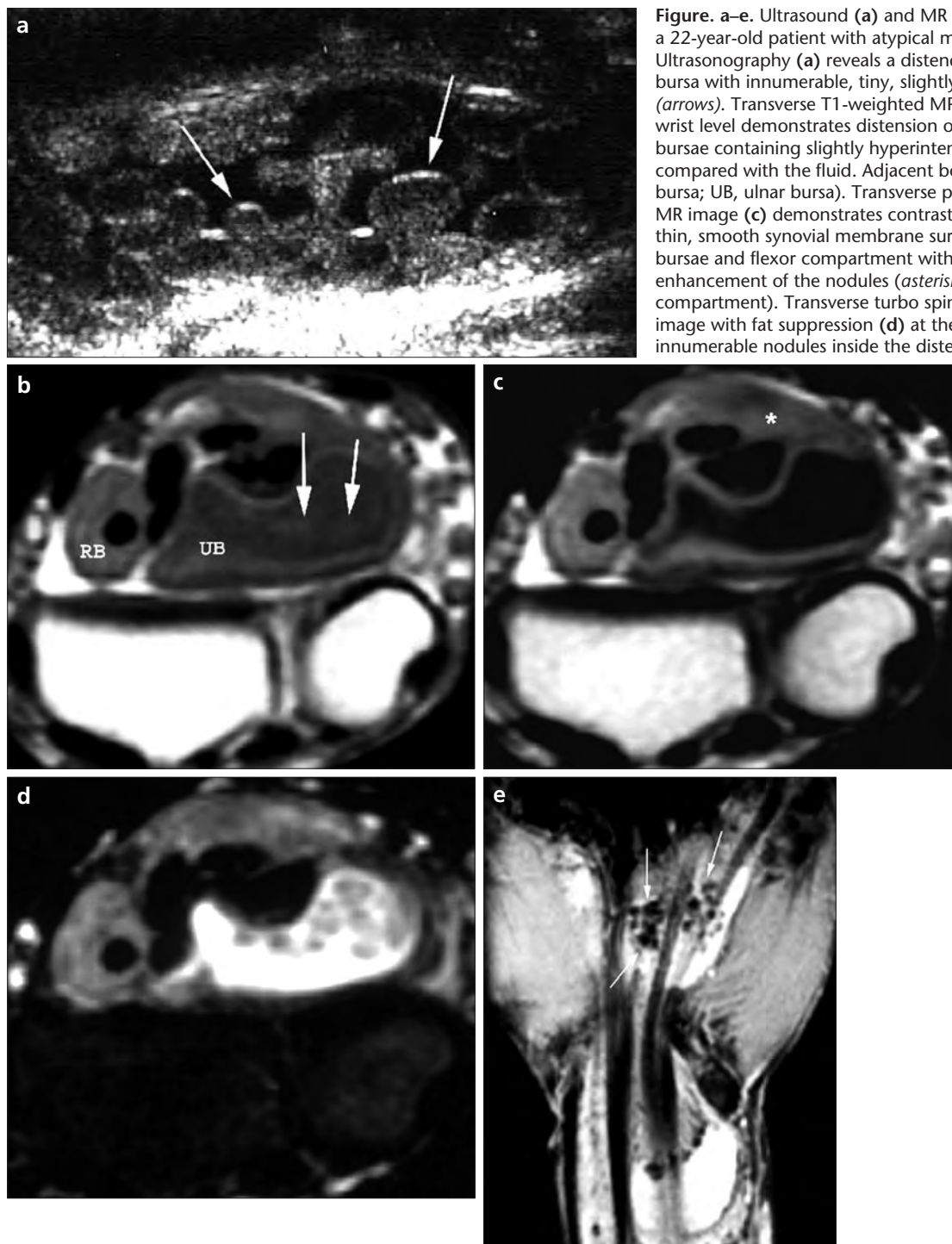


Figure. a–e. Ultrasound (a) and MR images (b–e) of the wrist of a 22-year-old patient with atypical mycobacterial tenosynovitis. Ultrasonography (a) reveals a distended tenosynovium and bursa with innumerable, tiny, slightly echogenic round nodules (arrows). Transverse T1-weighted MR image (b) at the proximal wrist level demonstrates distension of the radial and ulnar bursae containing slightly hyperintense nodules (arrows) as compared with the fluid. Adjacent bones are normal (RB, radial bursa; UB, ulnar bursa). Transverse postcontrast T1-weighted MR image (c) demonstrates contrast enhancement of the thin, smooth synovial membrane surrounding the distended bursae and flexor compartment with no evident contrast enhancement of the nodules (asterisk, synovitis of the flexor compartment). Transverse turbo spin-echo T2-weighted MR image with fat suppression (d) at the same level clearly shows innumerable nodules inside the distended bursa. These nodules

are hypointense relative to the fluid. On coronal gradient-echo MR image (e), the nodules are hypointense and are easily seen (arrows).

Discussion

While other mycobacteria grow in culture medium at 37°C, *Mycobacterium marinum*, an atypical *Mycobacterium* species, needs cooler temperatures, so theoretically rarely can cause infections involving deeper tissues of the body, such as tendon sheaths, joints, and bones. There have been reports in recent years of deep tissue infections

by *M. marinum*, particularly tenosynovitis of the wrist (1).

M. marinum is mainly found in contaminated water; thus fishermen and aquarium cleaners are at greater risk (2). The hand and wrist are the most frequent sites of atypical mycobacterial infection, thought to reflect the relative abundance of synovium in this region and likely occurrence of

pathogen inoculation through penetrating injuries (3). After inoculation of the organism through a wound or a cut, a slowly growing mass (tenosynovitis) becomes apparent in 1–2 months. Because physical signs and blood tests are nonspecific, diagnosis is often delayed a year or more. Delayed treatment may lead to complications, including tendon rupture,

osteomyelitis, permanent loss of motion, and even amputation (1).

Imaging plays an important role in establishing the diagnosis of tenosynovitis and directs the physician to investigate an atypical mycobacterial infection as the possible cause. So-called *rice bodies*, multiple nodules within the distended tendon sheaths of atypical mycobacterial infection, can be revealed by both sonography and MR imaging. Macroscopically resembling polished white rice, these nodules consist of an inner amorphous core of acidophilic material surrounded by collagen and fibrin (1). Their formation is postulated to be caused by synovial microinfarction or de novo formation within synovial fluid, followed by fibrin coverage (1). Rice bodies are not specific to this disease entity and can be observed also in rheumatoid arthritis, seronegative inflammatory arthritis, tuberculous tenosynovitis, and synovial chondromatosis (1, 3).

Rheumatologic disease as the origin of rice bodies and tenosynovitis can be excluded with proper history and examination findings of the patient (as what we had done). However, making a distinction from synovial chondromatosis is problematic; we were about to misinterpret the nodules within the distended tendon sheaths on the MRI examination as cartilaginous bodies, leading to incorrect diagnosis. Synovial chondromatosis is a benign monoarticular arthropathy presenting with inflammation, proliferation, and metaplasia of the synovium. Rarely,

the disease can affect extraarticular sites, such as synovial sheaths or bursae of the hand or foot (1, 4). Grossly, multiple gray-white nodules initially attached to the synovium may detach to form loose bodies. Histologically, these nodules consist of hyaline cartilage and a mineralized chondroid matrix. Rice bodies resemble synovial chondromatosis nodules, which can lead to diagnostic confusion in imaging. It has been reported that owing to the composition difference between rice bodies and cartilaginous nodules, rice bodies are almost imperceptible or faintly perceived on T1-weighted MR images, while uncalcified synovial chondromatosis may be mildly hyperintense (1). In our case, however, rice body formations were mildly hyperintense, in contrast to earlier reports. This may be caused by the fraction of granulomatous tissue structure of the rice bodies.

The occupation of the patient and the endemic conditions of *Mycobacterium* species in his living area made it necessary to send the aspirated material to microbiologic examination. The isolation and identification of *Mycobacterium* species by tissue culture is complicated and time consuming. Tissue culture of identifying the offending pathogen may take months to obtain a positive result. Recently, rapid detection and identification of different *Mycobacterium* species have been reported by using PCR (5).

Patients usually respond to synovectomy and antimycobacterial treatment. Surgery alone without use of

antimycobacterial agents carries the likelihood of recurrence.

In conclusion, this case highlights the following: (i) rice bodies may be found in atypical mycobacterial tenosynovitis; (ii) in evaluating tenosynovitis of the wrist with nodules, one must investigate also atypical *Mycobacterium*, particularly if suggested by endemic geography and occupation of patient; (iii) contrast-enhanced MR imaging is useful in depicting the extension of the synovitis; (iv) T1- or T2-weighted MR images are not helpful in distinguishing between the exact cause of nodules; and (v) PCR is a sensitive and specific method in identification of different mycobacterial species, allowing early diagnosis of the infection and treatment with surgery and antibiotics.

References

1. Lee EY, Rubin DA, Brown DM. Recurrent *Mycobacterium marinum* tenosynovitis of the wrist mimicking extraarticular synovial chondromatosis on MR images. *Skeletal Radiol* 2004; 33:405–408.
2. Ho MH, Ho CK, Chong LY. Atypical mycobacterial cutaneous infections in Hong Kong: 10-year retrospective study. *Hong Kong Med J* 2006; 12:21–26.
3. Chau CL, Griffith JF, Chan PT, Lui TH, Yu KS, Ngai WK. Rice-body formation in atypical mycobacterial tenosynovitis and bursitis: findings on sonography and MR imaging. *AJR Am J Roentgenol* 2003; 180:1455–1459.
4. Lazarus E, Song JH, Lambiase RE, Tung GA. General case of the day. Synovial chondromatosis. *Radiographics* 1996; 16:709–712.
5. Cai L, Chen X, Zhao T, Ding BC, Zhang JZ. Identification of *Mycobacterium marinum* 65 kD heat shock protein gene by polymerase chain reaction restriction analysis from lesions of swimming pool granuloma. *Chin Med J (Engl)* 2006; 119:43–48.